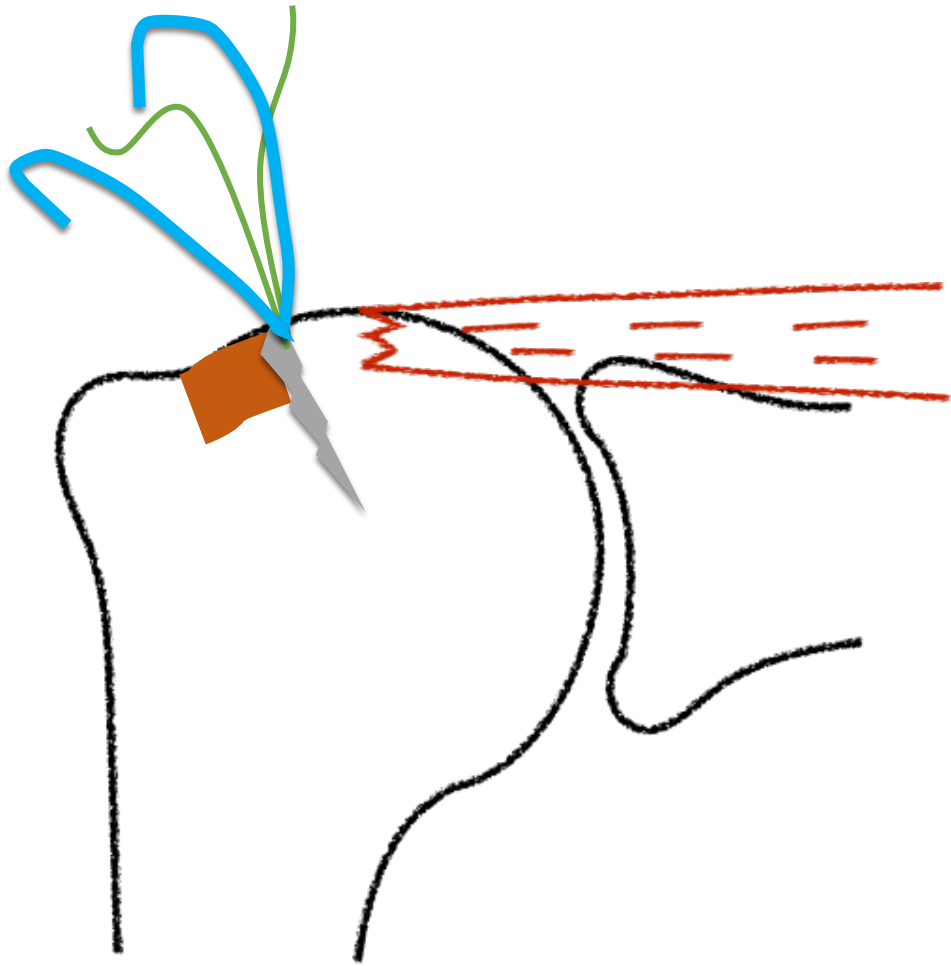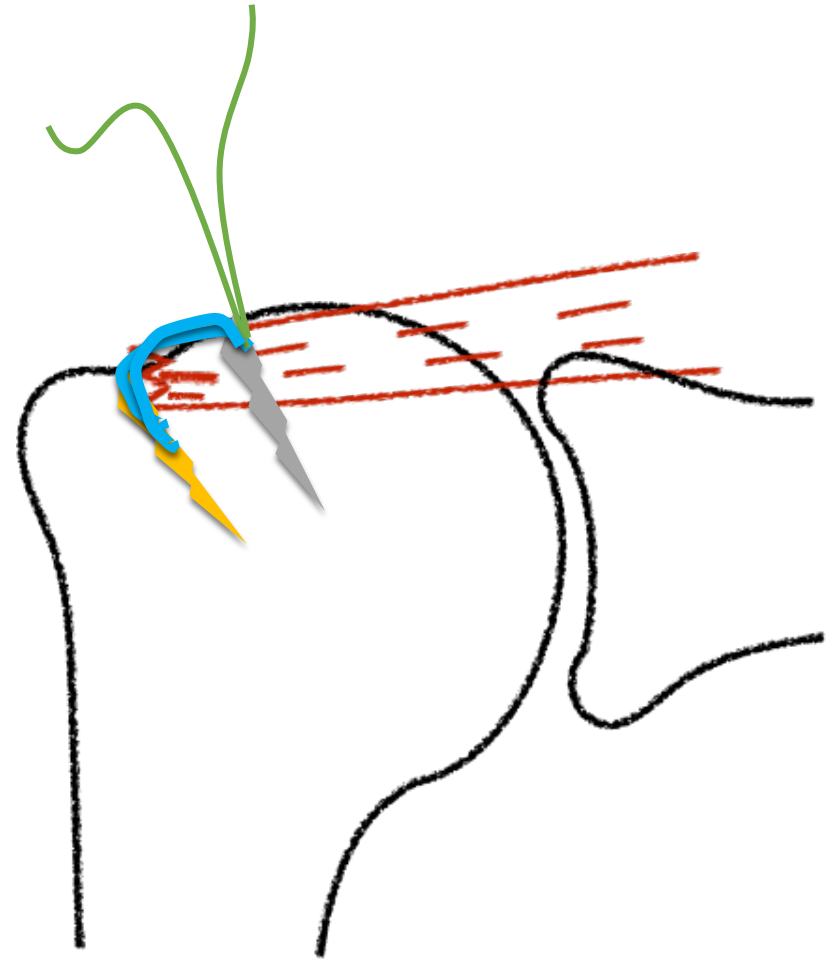


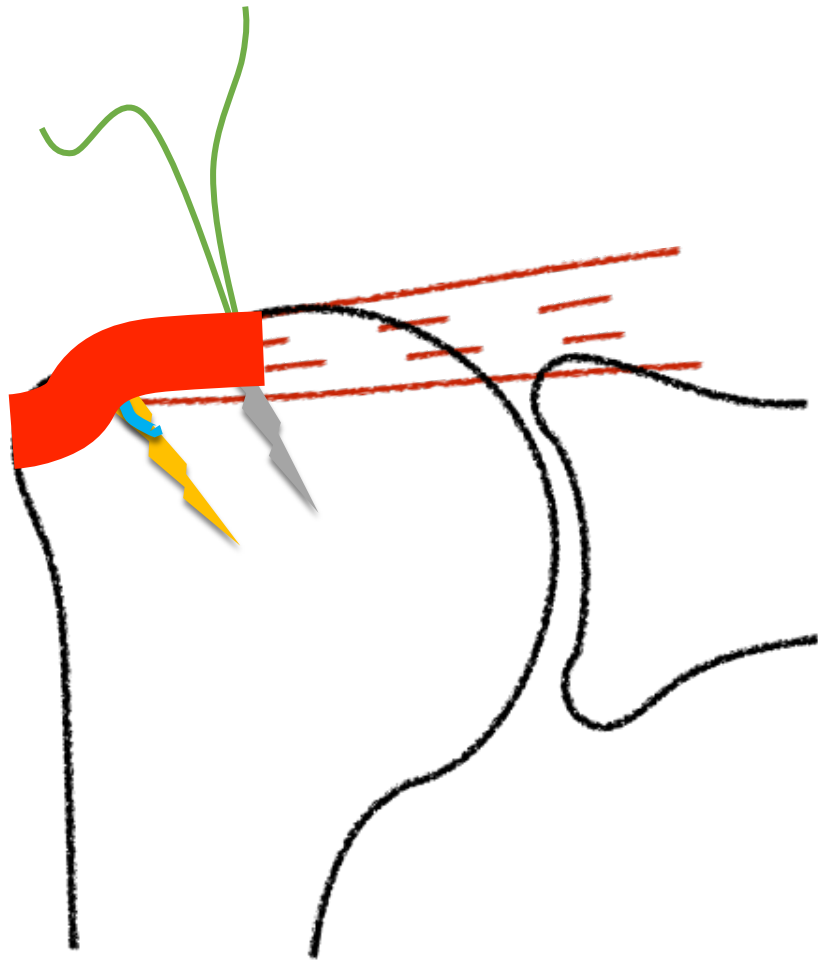
a



b

「 Postoperative outcomes of graft augmentation and ASCR for large and massive rotator cuff tears in patients younger than 80 years」

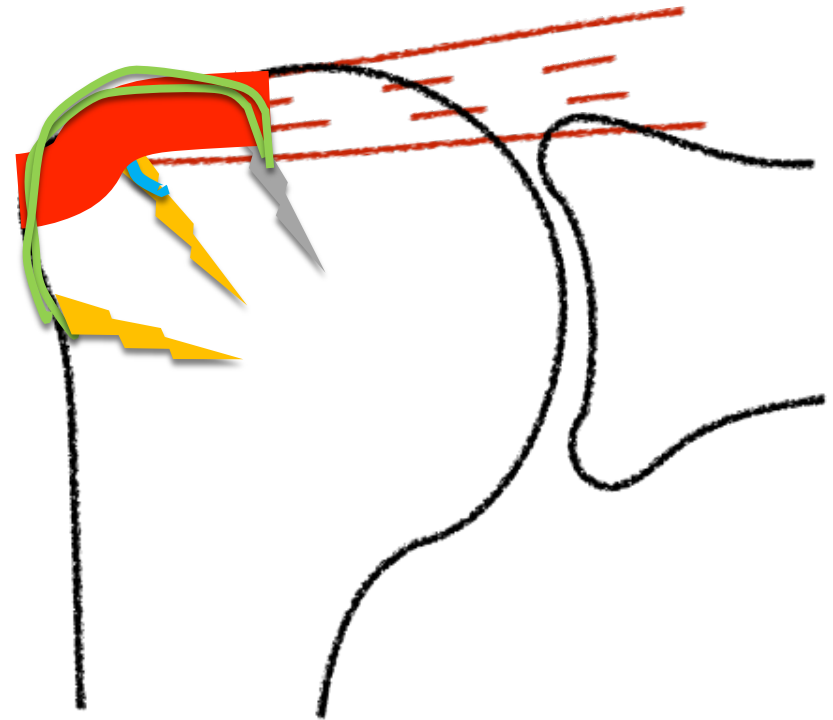
Satoru Ohta , JOSKAS Vol46:No.3,460-465,2021



c

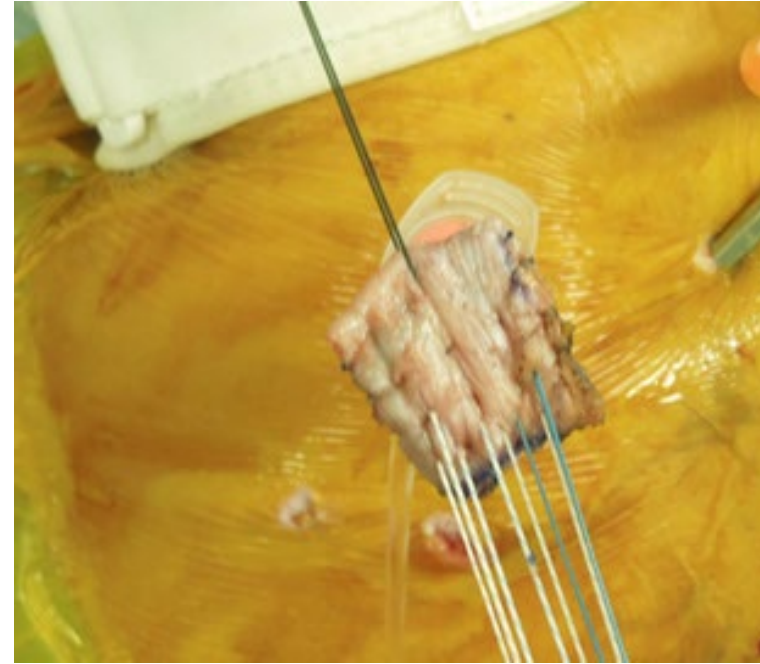
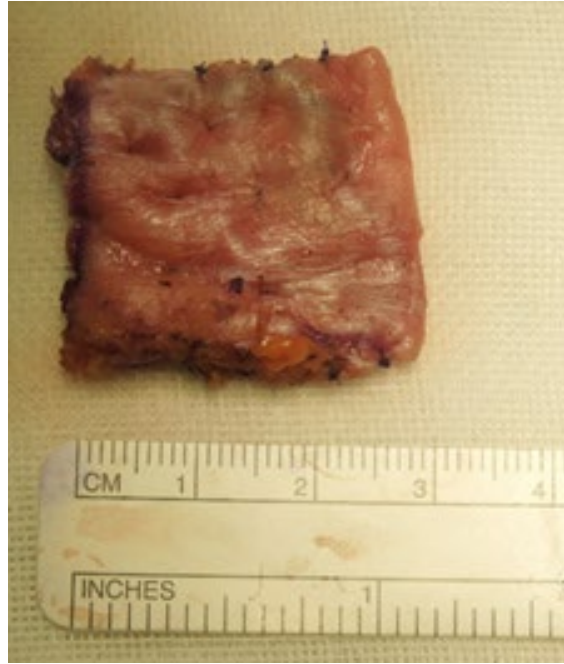

:Tensor fascialata



d

Double suture bridge method



harvested fascia lata
3 × 3 cm
4-6mm thickness

